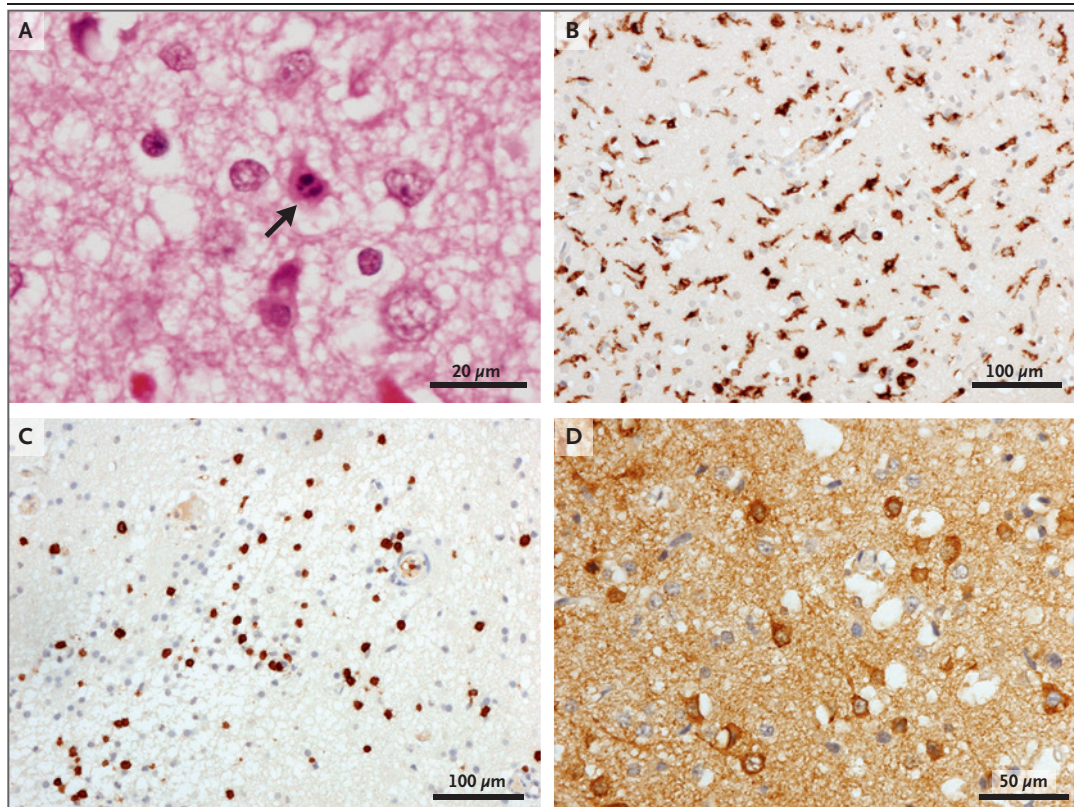


## Human Coronavirus OC43 Associated with Fatal Encephalitis

**TO THE EDITOR:** Encephalitis is a serious neurologic syndrome characterized by brain inflammation that may be fatal. Although the majority of cases are caused by viruses, the identification of a causal organism can be difficult. Encephalopathy that affects patients with immunodeficiency is particularly challenging to diagnose, since the clinical presentation may be atypical and the differential diagnosis may include unusual pathogens or a noninfective cause. Deep sequencing of clinical samples has the potential to identify the pathogens associated with encephalitis, particularly in cases in which traditional techniques have not identified the candidate causative pathogen.<sup>1</sup>

Here we report the use of deep sequencing of a brain biopsy sample obtained from an 11-month-old boy with severe combined immunodeficiency who had symptoms of viral encephalitis with negative results on conventional diagnostic polymerase-chain-reaction (PCR) assay. The boy's family provided written informed consent.

The boy underwent unconditioned cord-blood transplantation, which resulted in T-cell engraftment. Nonetheless, his condition continued to deteriorate, and he died 1.5 months after receiving the transplant. RNA sequencing of a brain biopsy sample obtained 2 months after the onset of symptoms showed the presence of human coronavirus OC43 (HCoV-OC43), which was sub-



**Figure 1. Immunohistochemical Analyses of Brain Tissue from an 11-Month-Old Boy with SCID and Symptoms of Viral Encephalitis.**

Panel A shows prominent vacuolation with frequent karyorrhectic neurons (arrow) in the cerebral cortex (hematoxylin and eosin) in an boy with severe combined immunodeficiency (SCID). A prominent microglial reaction was seen on CD68 immunohistochemical staining (Panel B), along with multiple collections of infiltrating T cells (Panel C). The nucleocapsid protein of human coronavirus OC43 showed positive staining in the neurons and neuropil (Panel D).

sequently confirmed on real-time PCR (threshold cycle, 24) and brain immunohistochemical analysis (Fig. 1). Full details on the case history, library preparation, bioinformatics analysis, species identification as reported by the profiling method metaMix,<sup>2</sup> PCR confirmation, immunohistochemical analysis, and phylogenetic and variant analyses are provided in the Supplementary Appendix, available with the full text of this letter at NEJM.org.

The human betacoronaviruses, including HCoV-OC43, are predominantly associated with respiratory tract infections. The group includes viruses that cause the severe acute respiratory syndrome and the Middle East respiratory syndrome. HCoV-OC43 is generally associated with mild upper respiratory tract infections, although it has been shown to have neuroinvasive properties. In vivo studies in mice have shown that HCoV-OC43 can infect neurons and cause encephalitis.<sup>3</sup> The virus has also been shown to cause persistent infections in human neural-cell lines.<sup>4</sup> A single report identified HCoV-OC43 RNA in the cerebrospinal fluid of a child with acute disseminated encephalomyelitis.<sup>5</sup> In the case we describe here, three independent methods were used to identify HCoV-OC43 in brain tissue of a child with acute encephalomyelitis.

Deep sequencing of biopsy material provides an important tool for the diagnosis of unexplained encephalomyelitis, particularly in patients with immunodeficiency who have undergone stem-cell transplantation, when the differential diagnosis may include immune-mediated inflammation or drug toxicity. The identification of a pathogen can provide important support for treatment decisions, such as changes in the immunosuppression regimen or the use of specific treatments. Standardization of protocols and analyses will aid in the development of this approach for the treatment of such patients.

Sofia Morfopoulou, Ph.D.

University College London  
London, United Kingdom  
sofia.morfopoulou.10@ucl.ac.uk

Julianne R. Brown, M.Sc.

E. Graham Davies, M.B., F.R.C.P.C.H.

Glenn Anderson, F.I.B.M.S.

Alex Virasami, M.Res.

Great Ormond Street Hospital for Children NHS Foundation Trust  
London, United Kingdom

Waseem Qasim, M.B., B.S., Ph.D.

University College London  
London, United Kingdom

Wui K. Chong, M.D.

Great Ormond Street Hospital for Children NHS Foundation Trust  
London, United Kingdom

Michael Hubank, Ph.D.

Vincent Plagnol, Ph.D.

University College London  
London, United Kingdom

Marc Desforges, Ph.D.

INRS-Institut Armand-Frappier  
Laval, QC, Canada

Thomas S. Jacques, Ph.D.

University College London  
London, United Kingdom

Pierre J. Talbot, Ph.D.

INRS-Institut Armand-Frappier  
Laval, QC, Canada

Judith Breuer, M.D.

University College London  
London, United Kingdom

Supported by the UCL National Institute for Health Research Biomedical Research Centres at University College London Hospitals and Great Ormond Street Hospital for Children NHS Foundation Trust.

Disclosure forms provided by the authors are available with the full text of this article at NEJM.org.

1. Brown JR, Morfopoulou S, Hubb J, et al. Astrovirus VA1/HMO-C: an increasingly recognized neurotropic pathogen in immunocompromised patients. *Clin Infect Dis* 2015;60:881-8.
2. Morfopoulou S, Plagnol V. Bayesian mixture analysis for metagenomic community profiling. *Bioinformatics* 2015;31:2930-8.
3. Talbot PJ, Desforges M, Brison E, Jacomy H. Coronaviruses as encephalitis-inducing infectious agents. In: Tkachev S, ed. *Non-flavivirus encephalitis*. Rijeka, Croatia: InTech, 2011:185-202.
4. Arbour N, Côté G, Lachance C, Tardieu M, Cashman NR, Talbot PJ. Acute and persistent infection of human neural cell lines by human coronavirus OC43. *J Virol* 1999;73:3338-50.
5. Yeh EA, Collins A, Cohen ME, Duffner PK, Faden H. Detection of coronavirus in the central nervous system of a child with acute disseminated encephalomyelitis. *Pediatrics* 2004;113(1 Pt 1):e73-6.

DOI: 10.1056/NEJMc1509458

Correspondence Copyright © 2016 Massachusetts Medical Society.

## CORRECTION

Zika and the Risk of Microcephaly (July 7, 2016;375:1-4). In Figure 1 (page 2), the second-trimester and third-trimester graphs (Panels D and F) were transposed. The article is correct at NEJM.org.